

CASE REPORT

Incidental diagnosis of 17 alpha-hydroxylase deficiency: a case report

Rasha Ammar^{1,*} and Ahmad Ramadan²¹Department of Obstetrics and Gynecology, Tishreen Hospital, Damascus, Syrian Arab Republic, ²Department of Cardiology, Tishreen Hospital, Damascus, Syrian Arab Republic

*Correspondence address. Tishreen Hospital, Damascus, Syrian Arab Republic. Tel: +963-948955618; E-Mail: ammar.n.rasha@gmail.com

Abstract

A 17 alpha-hydroxylase deficiency (17OHD) is a rare form of congenital adrenal hyperplasia (CAH). In this article we discuss a case of 8-year-old girl presented with upper respiratory infection symptoms and a history of hospital admission of fatigue and dehydration. She was incidentally found to have hypertension and hypokalemia. After an endocrine workup her biochemical tests showed: metabolic alkalosis, low levels of cortisol, high levels of adrenocorticotropic hormone (ACTH) and follicle-stimulating hormone (FSH) with normal female phenotype and (46,XY) karyotype. These findings led to the diagnosis of 17OHD confirmed by regression of hypertension and hypokalemia with hydrocortisone prescription. This case shows the importance of vital signs measurement, medical history and commitment to a systematic approach.

INTRODUCTION

Congenital adrenal hyperplasia (CAH) is a group of disorders resulting from defect of one of enzymes necessary for biosynthesis of cortisol. A 17 hydroxylase/17.20-lyase deficiency is a rare form of CAH, accounts about 1% of all cases [1]. It is an autosomal recessive defect in the cytochrome P450 17A1 enzyme which leads to impaired cortisol and sex steroid synthesis, with compensative elevation of adrenocorticotropic hormone (ACTH), gonadotropins [2], corticosterone and 11-deoxycorticosterone (DOC). In severe forms, patients usually have female phenotype and present with primary amenorrhea and absence of secondary sexual characteristics. Patients may have either a 46XX OR 46XY karyotype. We present a case of incidental diagnosis of (17 alpha-hydroxylase deficiency [17 OHD]) in a normal female phenotype child (46, XY karyotype) with hypokalemic hypertension.

CASE REPORT

A 8-year-old girl presented in pediatric clinic with upper respiratory infection symptoms: fever, cough, rhinorrhea and

pharyngodynia, no other accompanying signs or symptoms, a medical history of hospital admission of dehydration and fatigue, family history: older 14-year-old female sibling with uninvestigated primary amenorrhea and absence of secondary sexual characteristics. On physical examination: weight: 28 kg (69.497th percentile), height: 130 cm (62.225th percentile), BP 150/90 mmHg (99th percentile plus 5 mm Hg), Tanner stage: breast papilla elevation only (Stage1), pubic Hair: no pubic hair (Stage1), normal female external genitalia. Laboratory investigations: sodium = 142.78 mmol/L, potassium = 2.6 mmol/L, arterial blood gas (ph = 7.49, PaCO₂ = 22, PaO₂ = 96), Cortisol A.M = 3.09 ug/dl (normal = 6.2–19.4), ACTH = 198.3 pg/ml (normal = 5–60), aldosterone (standing) = 335.9 pg/ml (normal: supine = 10–160, standing = 35–300), plasma renin activity (PRA) (erect) = 0.61 ng/ml/h (normal: erect 0.98–4.18, supine: 0.51–2.64), follicle-stimulating hormone (FSH) = 31.65 mIU/ml (normal = 0.3–11), normal thyroid functions, metanephrine in 24 h urine sample = 0.79 (normal: up to 1), DHEA-S (dehydroepiandrosterone sulfate) = 2.47 ug/dl (normal: males 6–9 years: 10–85 ug/dl, females 6–9 years: 13–114), 17-OH progesterone (17-OHP) = 0.411 ng/ml (normal prepubertal: 0.07–153).

Received: July 10, 2020; Revised: September 20, 2020; Accepted: October 2, 2020

© The Author(s) 2020. Published by Oxford University Press. All rights reserved. For Permissions, please email: journals.permissions@oup.com

This is an Open Access article distributed under the terms of the Creative Commons Attribution Non-Commercial License (<http://creativecommons.org/licenses/by-nc/4.0/>), which permits non-commercial re-use, distribution, and reproduction in any medium, provided the original work is properly cited.

For commercial re-use, please contact journals.permissions@oup.com

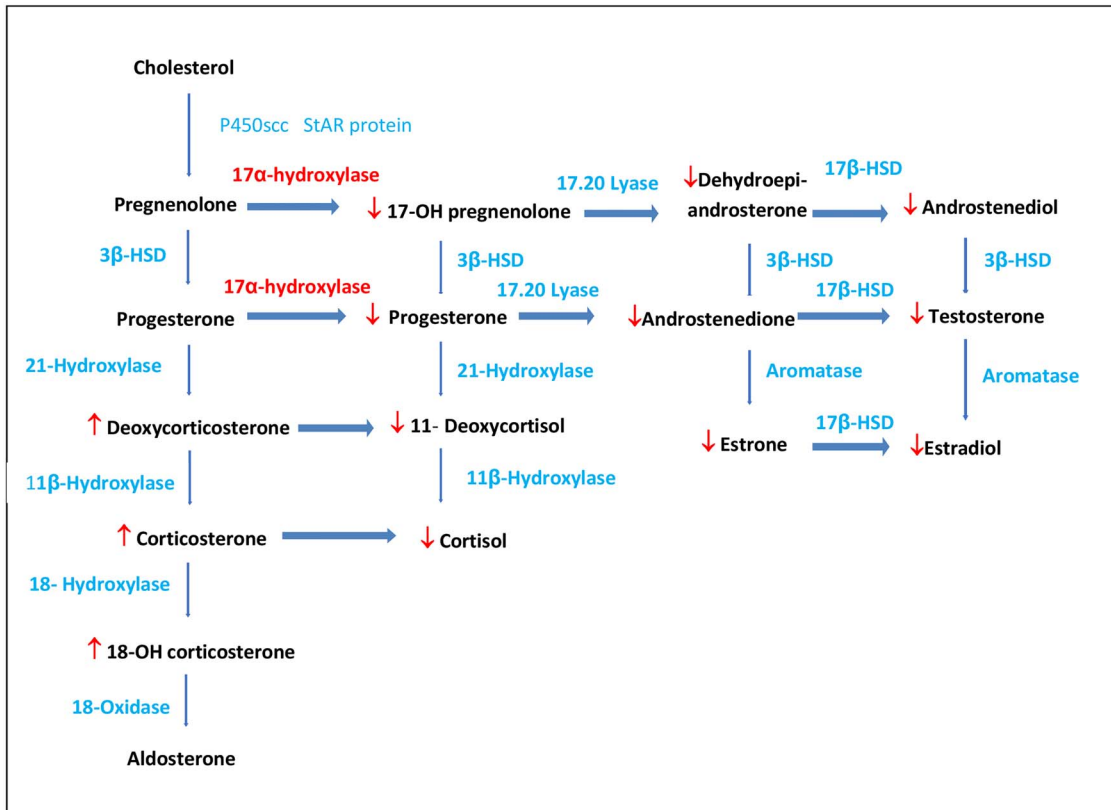


Figure 1: Adrenal steroidogenesis pathway.

Abdominal and pelvic ultrasound revealed no evidence of ureteral or ovarian tissues. Renal artery echo Doppler was within normal in both sides. Normal male karyotype (46,XY). Combination of hypokalemic hypertension, high aldosterone, low cortisol, high ACTH, high FSH and normal male karyotype (46XY) in a normal female phenotype at childhood led to the diagnosis of 17OHD. The patient was prescribed low dose hydrocortisone (10 mg/m²/day). After 3 months of treatment, a remarkable regression of high blood pressure value to normal range measuring 100/60 mm HG, biochemical laboratory tests showed: PRA (standing)=4.12 ng/ml/h, aldosterone 256.9 pg/ml (normal: supine=10–160, standing=35–300) compared to 0.61 ng/ml/h, 335.9 pg/ml, respectively before treatment.

DISCUSSION

Severe forms of 17OHD classically manifest in phenotypic females (who can have XX or XY) with: hypertension usually detected in early adulthood and can be severe, primary amenorrhea, absence of secondary sexual characteristics and minimal body hair [3]. Partial forms of 17OHD in 46XY patients (undervirilized male) present with: ambiguous genitalia, intra-abdominal or inguinal testes and blind vaginal pouch [3,4]. Mullerian structures (fallopian tubes, uterus and upper third of vagina) are absent due to normal production of mullerian inhibitory factor from testes. Deficient testosterone production explains development of external female genitals. 17OHD blocks synthesis pathways of cortisol and sexual hormones and induces the mineralocorticoid pathway synthesis resulting in decreasing of 17-OH pregnenolone, 17-OHP, 11-deoxycortisol,

cortisol, DHEA-S, androstenedione, testosterone [5] and over-production of 17-deoxysteroids by the adrenal cortex including DOC, corticosterone and 18-hydroxycorticosterone^{5,6}(18 OHB) (Fig. 1). High level of DOC induces sodium and fluid retention and loss of potassium and consequently hypertension because of its mineralocorticoid effect. Although low level of cortisone, patients with 17OHD rarely have adrenal crises because of corticosterone elevated levels of has some glucocorticoid activity preventing adrenal crises [5]. Most 17OHD patients have low aldosterone levels caused by increased levels of DOCs leading to suppression of renin angiotensin system. However, some cases reported high aldosterone levels [7,8]. Yamakita et al. explained the pathophysiology of high aldosterone levels with conversion of corticosterone to aldosterone by the elevated activity of corticosterone methyl oxidase produced by fasciculata cells [9]. Our case presented with incidentally discovered hypokalemic hypertension which was studied based on this differential diagnosis: CAH, primary aldosteronism, Cushing syndrome, pheochromocytoma, Liddle syndrome, renal vascular disease, androgen insensitivity syndrome and 5 α reductase deficiency. Laboratory investigations and imaging tests revealed: normal kidney artery resistance, normal 24 h urine metanephriane sample=0.79 excluding the diagnosis of pheochromocytoma, low cortisol A.M=3.09 Ug/dl excluding the diagnosis of Cushing syndrome, high Aldosterone (standing) =335.9 pg/ml, low DHEA-S=2.47ug/dl. These results led us to investigate the hypothalamic pituitary adrenal axis and hypothalamic pituitary gonadal axis; ACTH=198.3 pg/ml, FSH=31.65 mIU/ml. Decreased DHEA-S results in decreased testosterone excluding androgen insensitivity syndrome and 5 α reductase deficiency. The elevated ACTH level, low cortisol level, low DHEA-S level, high FSH level suggest suppression of both axes of hypothalamic pituitary

adrenal axis and hypothalamic pituitary gonadal axis. All these results in combination with hypokalemic hypertension led to the diagnosis of CAH with 17 OHD. Pelvic imaging revealed absence of uterus, ovarian tubes and cervix. Chromosome analysis revealed 46, XY karyotype. We were unable to perform plasma levels of DOC and 18 OHB which could confirm the diagnosis but as described earlier, clinical and available biochemical results supported the diagnosis of CAH due to 17OHD. Patients with 17 OHD have tall stature due to sex steroid deficiency causing epiphysis fusion failure; our patient's stature is within normal percentile similar to reported cases of 17 OHD patients with short or normal stature [10]. Hypertension usually resolves with glucocorticoid [6] therapy therefore the patient was treated with low-dose hydrocortisone (10 mg/m²/day) and a remarkable regression of high blood pressure, elevation of potassium serum within normal range, reduction of aldosterone level was noticed which supports the diagnosis of 17 a hydroxylase deficiency. At puberty age, development of female secondary sexual characteristic in 46,XY patients is induced by prescribing low-dose 17 beta estradiol patch (6.25 mcg/day) increased gradually every 6 months to reach target dose (25 mcg/day). Testes were not detected by ultrasonography. Detecting their position and performing gonadectomy is important, but in our case we were able to follow the patient for 3 months only, so we could not start sex steroid replacement therapy nor perform gonadectomy.

ACKNOWLEDGEMENTS

IN THE memory of Dr Mounzer Sayegh, head of Endocrinology Department at Tishreen Hospital who supported us and provided us with all medical information related to the case before he passed away. No funding was received for this study.

CONFLICT OF INTEREST STATEMENT

None declared.

ETHICAL APPROVAL

Ethical approval is not required for a case report in Syria.

CONSENT

A written consent was obtained from the patient's father because the patient is an underage child.

GUARANTOR

Rasha Ammar and Ahmad Ramadan.

REFERENCES

1. Krone N, Arlt W. Genetics of congenital adrenal hyperplasia. *Best Pract Res Clin Endocrinol Metab* 2009;23:181–92. doi: [10.1016/j.beem.2008.10.014](https://doi.org/10.1016/j.beem.2008.10.014).
2. Miller WL. Mechanisms in endocrinology: rare defects in adrenal steroidogenesis. *Eur J Endocrinol* 2018;179:125–41. doi: [10.1530/EJE-18-0279](https://doi.org/10.1530/EJE-18-0279).
3. Tian Q, Zhang Y, Lu Z. Partial 17 a -hydroxylase/17, 20-lyase deficiency – clinical report of five Chinese 46, XX cases. *Gynecol Endocrinol* 2008;24:362–7. doi: [10.1080/09513590802194051](https://doi.org/10.1080/09513590802194051).
4. Tiosano D, Knopf C, Koren I, Levanon N, Hartmann MF, Hochberg Z. Metabolic evidence for impaired 17 a -hydroxylase activity in a kindred bearing the E305G mutation for isolate 17 , 20-lyase activity. *Eur J Endocrinol* 2008;158:385–92. doi: [10.1530/EJE-07-0712](https://doi.org/10.1530/EJE-07-0712).
5. Kim SM, Rhee JH. A case of 17 alpha-hydroxylase deficiency. *Clin Exp Reprod Med* 2015;42:72–6. doi: [10.5653/cerm.2015.42.2.72](https://doi.org/10.5653/cerm.2015.42.2.72).
6. Wong SL, Shu SG, Tsai CR. Seventeen alpha-hydroxylase deficiency. *J Formos Med Assoc* 2006;105:177–81. doi: [10.1016/S0929-6646\(09\)60342-9](https://doi.org/10.1016/S0929-6646(09)60342-9).
7. Cottrell DA, Bello FA, Falko JM. Masquerading as primary Hyperaldosteronism. *Am J Med Sci* 1990;300:380–2. doi: [10.1097/00000441-199012000-00007](https://doi.org/10.1097/00000441-199012000-00007).
8. Yanase T, Simpson ER, Waterman MR. Investigation to molecular definition. *Endocr Rev* 1991;12:91–108. doi: [10.1210/edrv-12-1-91](https://doi.org/10.1210/edrv-12-1-91).
9. Yamakita N, Murase J, Yasuda K, Noritake N, Mercado-Asis L, Miura K. Possible Hyperaldosteronism and discrepancy in enzyme activity deficiency in adrenal and gonadal glands in Japanese patients with 17a-hydroxylase deficiency. *Endocrinol Jpn* 1989;36:515–36. doi: [10.1507/endocrj1954.36.515](https://doi.org/10.1507/endocrj1954.36.515).
10. Kardlen A, Toksoy G, Baş F, Abali Z, Gençay G, Poyrazoğlu S et al. A rare cause of congenital hyperplasia: clinical and genetic findings and follow-up characteristics of six patients with 17-hydroxylase deficiency including two novel mutations. *J Clin Res Pediatr Endocrinol* 2018;10:206–15. doi: [10.4274/jcrpe.0032](https://doi.org/10.4274/jcrpe.0032).